



Disponible en ligne sur

**ScienceDirect**  
 www.sciencedirect.com

Elsevier Masson France

**EM|consulte**  
 www.em-consulte.com


## Review article

# Paediatric brain tumours: A review of radiotherapy, state of the art and challenges for the future regarding protontherapy and carbontherapy



## *Tumeurs cérébrales pédiatriques : revue de la littérature en radiothérapie, état de l'art et défis pour l'avenir en ce qui concerne la protonthérapie et la carbonothérapie*

A. Laprie<sup>a,b,\*,c</sup>, Y. Hu<sup>d</sup>, C. Alapetite<sup>e</sup>, C. Carrie<sup>d,f</sup>, J.-L. Habrand<sup>e,g,h,i,j</sup>, S. Bolle<sup>e,k</sup>, P.-Y. Bondiau<sup>l,m</sup>, A. Ducassou<sup>b,c</sup>, A. Huchet<sup>n</sup>, A.-I. Bertozzi<sup>c,o</sup>, Y. Perel<sup>o</sup>, É. Moyal<sup>a,b,c</sup>, J. Balosso<sup>d,p</sup>, on behalf of the radiotherapy committee of SFCE and France Hadron<sup>1</sup>

<sup>a</sup> Université Paul-Sabatier, Toulouse, France<sup>b</sup> Institut Claudius-Regaud, institut universitaire du cancer de Toulouse (IUCT)-Oncopole, radiation oncology, 1, avenue Irene-Joliot-Curie, 31059 Toulouse, France<sup>c</sup> Périclès-France-Hadron, Toulouse, France<sup>d</sup> GCS-Étoile-France-Hadron, Lyon, France<sup>e</sup> Institut Curie Paris Orsay (ICPO)-France-Hadron, Orsay, France<sup>f</sup> Centre Léon-Bérard, Lyon, France<sup>g</sup> Université Paris Sud, Orsay, France<sup>h</sup> Archade-France-Hadron, Caen, France<sup>i</sup> Centre François-Baclesse, Caen, France<sup>j</sup> Gustave-Roussy, Villejuif, France<sup>k</sup> Impact-France-Hadron, Nice, France<sup>l</sup> Centre Antoine-Lacassagne, Nice, France<sup>m</sup> CHU de Bordeaux, Bordeaux, France<sup>n</sup> Hôpital des Enfants, Toulouse, France<sup>o</sup> Université Grenoble Alpes, Grenoble, France<sup>p</sup> CHU de Grenoble, Grenoble, France

## ARTICLE INFO

## Article history:

Received 17 December 2014

Received in revised form 18 May 2015

Accepted 21 May 2015

## Keywords:

Paediatric brain tumour

Protontherapy

Carbontherapy

Ependymoma

Craniopharyngioma

Medulloblastoma

Craniospinal irradiation

Germ-cell tumours

## ABSTRACT

**Background and purpose.** – Brain tumours are the most frequent solid tumours in children and the most frequent radiotherapy indications in paediatrics, with frequent late effects: cognitive, osseous, visual, auditory and hormonal. A better protection of healthy tissues by improved beam ballistics, with particle therapy, is expected to decrease significantly late effects without decreasing local control and survival. This article reviews the scientific literature to advocate indications of protontherapy and carbon ion therapy for childhood central nervous system cancer, and estimate the expected therapeutic benefits.

**Materials and methods.** – A systematic review was performed on paediatric brain tumour treatments using Medline (from 1966 to March of 2014). To be included, clinical trials had to meet the following criteria: age of patients 18 years or younger, treated with radiation, and report of survival. Studies were also selected according to the evidence level. A secondary search of cited references found other studies about cognitive functions, quality of life, the comparison of photon and proton dosimetry showing potential dose escalation and/or sparing of organs at risk with protontherapy; and studies on dosimetric and technical issues related to protontherapy.

**Results.** – A total of 7051 primary references published were retrieved, among which 40 clinical studies and 60 papers about quality of life, dose distribution and dosimetry were analysed, as well as the ongoing clinical trials. These papers have been summarized and reported in a specific document made available to

\* Corresponding author.

E-mail address: laprie.anne@iuct-oncopole.fr (A. Laprie).

<sup>1</sup> SFCE : Société française de lutte contre les cancers et les leucémies de l'enfant et de l'adolescent (French society of childhood cancers).<http://dx.doi.org/10.1016/j.canrad.2015.05.028>

1278-3218/© 2015 Published by Elsevier Masson SAS on behalf of the Société française de radiothérapie oncologique (SFRO).

the participants of a final 1-day workshop. Tumours of the meningeal envelop and bony cranial structures were excluded from the analysis. Protontherapy allows outstanding ballistics to target the tumour area, while substantially decreasing radiation dose to the normal tissues. There are many indications of protontherapy for paediatric brain tumours in curative intent, either for localized treatment of ependymomas, germ-cell tumours, craniopharyngiomas, low-grade gliomas; or panventricular irradiation of pure non-secreting germinoma; or craniospinal irradiation of medulloblastomas and metastatic pure germinomas. Carbon ion therapy is just emerging and may be studied for highly aggressive and radioresistant tumours, as an initial treatment for diffuse brainstem gliomas, and for relapse of high-grade gliomas.

**Conclusion.** – Both protontherapy and carbon ion therapy are promising for paediatric brain tumours. The benefit of decreasing late effects without altering survival has been described for most paediatric brain tumours with protontherapy and is currently assessed in ongoing clinical trials with up-to-date proton devices. Unfortunately, in 2015, only a minority of paediatric patients in France can receive protontherapy due to the lack of equipment.

© 2015 Published by Elsevier Masson SAS on behalf of the Société française de radiothérapie oncologique (SFRO).

## R É S U M É

### Mots clés :

Tumeurs cérébrales pédiatriques  
Protonthérapie  
Thérapie par ions carbone  
Épendymome  
Craniopharyngiome  
Médulloblastome  
Irradiation crâniospinale  
Tumeur germinale

**Objectifs.** – Les tumeurs cérébrales sont l'indication de radiothérapie pédiatrique la plus fréquente, avec des effets tardifs fréquents : cognitifs, osseux, visuels, auditifs et hormonaux. En raison de leur balistique exceptionnelle, les faisceaux de particules pourraient apporter une meilleure protection des tissus sains sans diminuer le contrôle local et la survie. Cet article est une revue de la littérature scientifique ayant pour but de proposer les indications de protonthérapie et de thérapie par ions carbone pour les tumeurs cérébrales pédiatriques et d'estimer les bénéfices thérapeutiques escomptés.

**Matériel et méthodes.** – Une revue systématique a été réalisée sur les essais cliniques de radiothérapie des tumeurs pédiatriques en utilisant Medline (de 1966 à mars 2014), selon les critères suivants : patients âgés de 18 ans ou moins, ayant reçu une radiothérapie et comportant des données de survie. Les études sur les fonctions cognitives, la qualité de vie, la comparaison dosimétrique photons–protons ont également été incluses.

**Résultats.** – Sur 7051 références primaires publiées, 40 études cliniques et 60 articles de qualité de la vie et dosimétrie ont été analysés, ainsi que les essais cliniques en cours. Ces documents ont été condensés et présentés dans un document spécifique mis à la disposition des experts participant à un atelier final d'une journée. Il existe de nombreuses indications de protonthérapie pour les tumeurs cérébrales pédiatriques à visée curative : pour le traitement localisé des épendymomes, tumeurs germinales, craniopharyngiomes, gliomes de bas grade, pour l'irradiation pan-ventriculaire des germinomes purs non-sécrétant et pour l'irradiation crâniospinale des médulloblastomes et germinomes purs métastatiques. La thérapie par ions carbone est en train d'émerger et pourrait être étudiée pour les tumeurs très agressives et radiorésistantes, tels les gliomes du tronc cérébral diffus, et les rechutes des gliomes de haut grade.

**Conclusion.** – Pour les tumeurs cérébrales pédiatriques, protonthérapie et thérapie par ions carbone sont prometteuses. L'avantage de diminuer les effets tardifs sans altérer la survie a été décrit pour la plupart des tumeurs cérébrales pédiatriques avec la protonthérapie et est en évaluation dans des essais cliniques en cours. Actuellement, en France, une minorité de patients pédiatriques reçoit une protonthérapie en raison du manque d'équipement.

© 2015 Publié par Elsevier Masson SAS pour la Société française de radiothérapie oncologique (SFRO).

## 1. Introduction

### 1.1. Radiotherapy for paediatric brain tumours

Brain tumours are the most frequent paediatric solid tumours in children. In most cases, treatment includes surgery and radiotherapy with or without chemotherapy. Paediatric brain tumours acutely raise the question of treatments long-term tolerance. According to paediatric brain tumour natural history, the treatment is either addressing the general spreading of the disease or the local invasion and often both. Whenever the local control is the upfront challenge for the cure rate, the role of surgery and radiation therapy is important. The main drawback of radiation therapy is its acute and late toxicity that are particularly serious for central nervous system in childhood. Intelligence quotient impairment and other functional loss are well-documented. The challenge is therefore to improve the local control with less toxicity by identifying very accurately the target and avoiding irradiation of normal tissues outside the target.

Although surgery could be improved by postoperative assessment and sophisticated imaging, more improvement could come

from altered radiotherapy technics as particle therapy. Actually, the better dose localization of particle therapy opens the possibility to increase target dose and to decrease organs at risk dose in the same time. Even more, in case of really very radioresistant tumours, heavy ions could be used with the same possibility of organs at risk sparing. Actually, protontherapy is a highly conformal treatment, able to reduce the absorbed dose to the normal brain parenchyma, the optic pathways, hypothalamus and sensorial organs.

However, one should consider also the risk of undue relapses while changing from larger integrated dose with photons to more localized dose of protons, due to uncertainties of the microscopic extend of the disease [1]. Similarly, uncertainties are remaining about the relative biological efficiency of particle therapy especially for children normal brain, and for tumours.

Thus, a complex figure of multiple parameters is existing in the domain of paediatric tumours including pattern of spreading and relapse, targets nature and location, tumour sensitivity, age of the patients, side-effects risk, that are influencing the possibilities of improvement by the use of particle therapy.

In France, presently, there is only one high-energy protontherapy center (ICPO, Orsay) able to treat such tumours [2]. The

other French protontherapy center (Impact/Médicyc, Nice) is getting upgraded to access high energy, and there are several other projects. There is a need to determine how many regional referral centres, equipped with such technique, are necessary in France. An analysis of all indications for adults and children must be performed. This prompted the radiotherapy committee of the French society of childhood cancers (Société française de lutte contre les cancers et les leucémies de l'enfant et de l'adolescent [SFCE]), to join the France Hadron consortium to define the indications of particle therapy for paediatric brain tumours. The France Hadron consortium includes existing particle therapy centres (ICPO in Orsay and Impact/Medicyc in Nice), as well as projects (centre Étoile in Lyon, Archade in Caen, Périclès in Toulouse).

The present paper reviews the toxicity and impairment data regarding paediatric central nervous system tumours, then details, for each type of paediatric brain tumours, the present challenges, the contribution of radiotherapy as a treatment component and the possibilities to improve it including by the use of particle therapy, and, how to assess this by evidence-based medicine approaches.

### 1.2. Late effects of paediatric cerebral radiation therapy

Cognitive dysfunction and endocrinopathy are the most frequent side effects of brain radiation therapy. Depending on tumour location; auditive and visual impairment are also frequent. Vasculopathy with stroke and second cancers are much less frequent.

Additionally, in case of craniospinal irradiation, decreased bone growth is constant, risks on lung and heart function do exist [3–5]. Moreover, the use of anticancer agent is a cause of second cancer.

## 2. Methods

Prior to the literature research, an expert group identified the potential indications for hadrontherapy (proton and carbon) in terms of tumour location and/or histology according to basic principle. These principles were: radioresistant unresectable tumours surrounded by organ at risk, with mainly local-regional spreading for patients lacking heavy comorbidities.

The Medline database and Cochrane Library (from January 1966 to March 2014) were used to perform the search. The query equation was made of combinations of tumours and treatments names: “paediatric/childhood”, “central nervous system cancer” (including all brain tumour types), and “radiotherapy” (including all types of radiotherapy). Tumours of the meningeal envelopes and bony cranial structures have been excluded from the analysis.

Only papers in English were considered and then selected on their titles and abstracts; a second selection was done by reading the full papers. To be included, clinical trials had to meet the following criteria: patient's median age 18 years or less, patients receive a radiotherapy, and the study reported survival results, relevant clinical outcomes, and substantial duration of follow-up. Furthermore, to be compared with photon, dosimetric studies were also included in this analysis. Because of the childhood population, papers about cognitive function and quality of life were included. When several papers were related to the same study, only the most recent one has been used. Clinical studies were selected according to their levels of evidence (randomized controlled trials > controlled trials > non-controlled observation trials). The information collected was: study design, patients' characteristics, radiation modality, radiation dose and fraction, and patient outcomes. The primary endpoint was local control. The secondary endpoints were overall survival and late toxicity.

As a whole, 7051 primary references were retrieved among which 40 report on clinical studies and 60 papers about quality of life, dose distribution and dosimetry were analysed, as well as the descriptions of the ongoing clinical trials. These papers have been summarized and reported in a specific document made available to the participants of a final 1-day workshop. The literature review has been summarized in a report submitted to a group of experts on brain tumours, and then proton and carbon radiotherapy indications have been discussed during a 1-day workshop whose conclusions are the base of the present paper.

## 3. Results

### 3.1. Gliomas

Glioma, according to their pathological grade and anatomic location, are of different level of life-threatening seriousness which is described thereafter (Table 1).

Low-grade gliomas are the most commonly diagnosed brain tumour in children and the most common cause of child brain irradiation. The overall survival rate being rather good, the main concern is the treatment related late toxicity, which justifies the search for alternatives to the use of radiotherapy.

High-grade glioma are rare in children but have a very poor prognosis [10,11]. They are very infiltrative needing large volume to treat and consequently represent poor indication for radiation therapy, although applied on a regular basis.

#### 3.1.1. Optic pathway glioma

Optic pathway gliomas represent 1–5% of all gliomas in childhood. These low-grade gliomas are associated with type 1 neurofibromatosis (NF1) in 18–70% of cases. They differ in their natural history according to their location along the optic-tract. As long as there is no clinical or imaging progression, follow-up is just recommended. When neurosurgery is done for distal location of tumours, it results in blindness of the involved eye. However, in case of chiasmatic or proximal location, surgery would lead to unacceptable side effects; therefore, radiation therapy is recommended (Fig. 1).

Radiation therapy proved to improve local control and relapse-free survival [7]. A recent study, which compared protontherapy versus 3D-photon radiation therapy, showed that protontherapy offered a high degree of conformity to target volumes and substantial normal-tissue sparing in both high and low-dose areas. Advantages of protontherapy versus 3D-photon radiation therapy are increasingly apparent with increasing target size and tumour complexity. However, the indication for radiation therapy remains limited to symptomatic tumour growth. Another approach could be to broaden the use of protontherapy to earlier cases to treat smaller volumes, as suggested by a study reporting lower risks of visual loss with upfront photon radiation therapy compared with post-chemoradiation therapy [12]. Protontherapy, being safer than photon radiation therapy, its earlier use should allow better visual protection. [6].

#### 3.1.2. Low-grade glioma

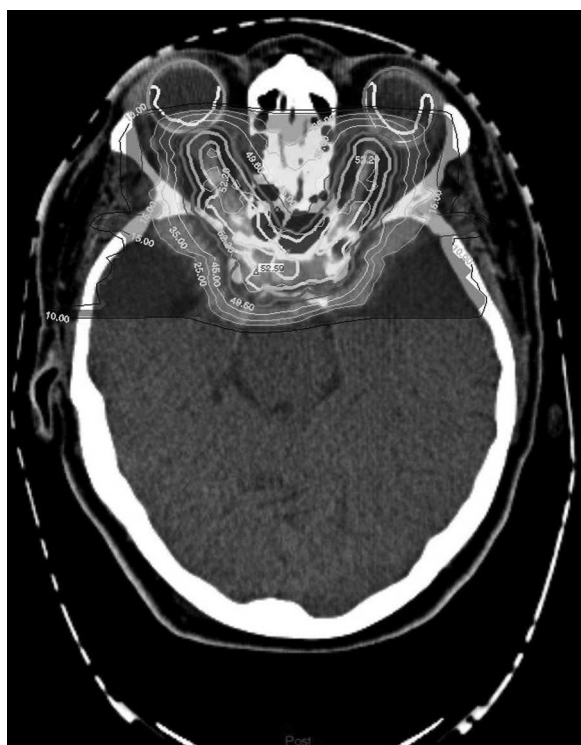
Low-grade gliomas account for 30% to 50% of paediatric brain tumours and can occur at all ages. Surgery alone may be curative, but radiation therapy will ultimately be required for most patients, especially when the tumour is central, and involves the diencephalon and optic pathways. The overall survival rate, when complete resection, are around 80% to 90% at 10 years. The long-term cumulative risks of radiation therapy late effects have

**Table 1**  
Published studies on glioma treatments in children.

Study	Treatment				Number of patients	Efficacy	
	Induction chemotherapy	Proton	Photon	Adjuvant chemotherapy		Overall survival	Event-free survival
<i>Pediatric optic pathway glioma</i>							
Fuss et al., 1999 [6]	–	54 CGE in 6 patients CGE in 1 patient		–	7	Time all alive without evidence of local recurrence	
Combs et al., 2005 [7]	–		Fractionated stereotactic radiotherapy: median dose 52.2 Gy, 1.8 Gy/fraction	–	15	3-year: 100% 5-year: 90%	3-year PFS: 92% 5-year PFS: 72%
<i>Pediatric low grade glioma</i>							
Merchant et al., 2009 [8]	–		Conformal radiotherapy: 54 Gy, 1.8 Gy/fraction, prior chemotherapy in 25 patients		78	5-year: 98.5 % 10-year: 95.9 %	5-year PFS: 87.4% 10-year PFS: 74.3%
Hug et al., 2002 [9]		50.4 CGE-63 CGE, 1.8 CGE/fraction/d			27s	85% (mean follow-up 39 months)	Local control: 78% (mean follow-up 39 months)
<i>High grade glioma treated by chemoradiotherapy</i>							
MacDonald et al., 2005 (CCG 9933) [10]	Carboplatin/etoposide (A) Ifosfamide/etoposide (B) Cyclophosphamide/etoposide (C)	–	54 Gy + boost 5.4 Gy, 1.8 Gy/fraction	Lomustine + vincristine	23 27 26	24% No difference between the three regimens	8% No difference between the three regimens

CGE: cobalt gray equivalent; PFS: progression-free survival.

prompted the search for alternatives to reduce the long-term side effects for children. However, the tremendous progress of radiotherapy in the last decade justifies studies to reassess the benefit of radiation therapy.



**Fig. 1.** Radiotherapy of optic pathways glioma in a child: 52.2 Gy given to both optic pathways; dose constraints to posterior and anterior parts of the eye were respected. The dose delivered to a part of the temporal lobes was a median of 10 Gy. Courtesy of Dr S. Bolle, centre de protonthérapie d'Orsay.

**3.1.2.1. Published studies on radiation therapy for low-grade gliomas.** Two recent studies, based on prospective trials in two different institutions, confirmed the hypothesis that irradiation with only 10 mm of clinical target volume (CTV) margin did not affect the rate of treatment failure in paediatric low-grade gliomas [8,13]. This decreased planning target volume (PTV) may reduce the cognitive effects [14]. Furthermore, it is now considered that the CTV margin could be further reduced to 5 mm. Another result is that the 4% rate of vasculopathy is even more important in young children and in patients with a type-1 neurofibromatosis (NF1) [7]. Another study, from the same authors, shows that the cognitive effects of radiation therapy correlated with the patient's age, NF1 status, tumour location and volume, extent of resection, and radiation dose [15]. The effect of age exceeded that of radiation dose, with patients younger than 5 years experiencing the greatest decline in cognition.

A retrospective study of protontherapy for low-grade gliomas has showed the safety and efficacy of this technique, making low-grade glioma a potentially good indication of protontherapy when radiation therapy is needed, especially in cases of large (more than 4 cm) or complex volumes, and in cases of close proximity to sensitive structures [9]. However, caution is needed for baseline evaluation and follow-up, and it should be noted that NF1 patients' (25% of low-grade gliomas) appear to have a higher baseline rates of vasculopathy, and that children before 5 years old are more radiosensitive.

**3.1.2.2. Ongoing studies on radiation therapy for low-grade gliomas.** A large COG phase II study of conformal radiotherapy in patients with low grade gliomas, with reduced margins using photons or protons, is described at: <http://clinicaltrials.gov/ct2/show/NCT00238264?term=astrocytoma&recr=Open&intr=radiotherapy&outc=survival&age=0&rank=3>.

Event-free survival was designed as the primary endpoint, and quality of life is also assessed.

### 3.1.3. High-grade glioma

High-grade gliomas represent approximately 10% of all paediatric brain tumours. They are very infiltrative; thus treatment volumes have to be very large. Their prognosis is very poor despite a variety of therapies including chemotherapy and radiotherapy (Table 1) [10,11]. High-grade glioma is one of the leading causes of cancer-related deaths in children with a current 2-year survival rate of 10–30% [16]. Whenever possible, children undergo surgery followed by radiation therapy with chemotherapy. External radiation therapy targeting the resected site of the tumour has been shown to improve survival when compared to surgery alone, and it is therefore considered as the standard of care.

**3.1.3.1. Published studies on radiation therapy for high-grade gliomas.** Combs et al. described, in-vitro, that high linear energy transfer (LET) carbon-ion irradiation was significantly more effective at destroying glioblastoma cell lines compared to photon irradiation; this is quoted to the due to the high relative biological efficiency of carbon ions [17].

Since patients experience frequent in-field incurable relapses, it could be of interest to test carbon ions therapy for re-irradiation of limited volumes. Treatment of patients with recurrence includes surgery, chemotherapy, or re-irradiation. Re-irradiation needs to be done with caution, but has improved survival in adult studies [18]. As carbon ions offer optimal delivery within the spread of the Bragg peak, a prospective phase III trial, named Cinderella, is currently ongoing that includes adult patients receiving carbon re-irradiation for high-grade gliomas [19]. Depending on the results of this study, this approach could be applied to children. Because of the large volumes to be irradiated and the poor survival rates, high-grade glioma is not a primary indication for protontherapy.

**3.1.3.2. Ongoing studies on treatments for high-grade gliomas.** To date, there are, on the NCI site, many (approximately 20) phases I and II ongoing studies of targeted drugs associated with radiotherapy in children with diffuse intrinsic pontine gliomas and high grade gliomas, but no protontherapy trial are ongoing for these tumours: <http://clinicaltrials.gov/ct2/results?term=high+grade+glioma+paediatric&Search=Search>.

### 3.1.4. Diffuse intrinsic pontine gliomas

Diffuse intrinsic pontine gliomas represent 80% of paediatric brainstem gliomas and ~10% of all paediatric brain tumours. Following radiation therapy, which is the main treatment, the majority of patients improve clinically. However, diffuse intrinsic pontine glioma carries a bleak prognosis as the progression-free interval is usually shorter than 6 months and survival is poor, with median survival times of less than 1-year and 2-year survival rates <20%. Many new therapies have been evaluated for diffuse intrinsic pontine gliomas over the last 2 decades, including radiation-dose escalation with hyperfractionated- or accelerated radiation therapy, pre-irradiation chemotherapy, high-dose chemotherapy and new radiosensitizers [20–25]. Unlike other types of paediatric brain tumours, little progress has been made in the treatment of diffuse intrinsic pontine gliomas [26]. Therefore, there is a need for new paradigms of treatment [27]. The ballistics of proton therapy would not bring benefit for dose escalation and the lesser risk of late effects cannot be expected for these children. Carbon ion therapy, due to its higher relative biological efficiency, should be tested in this radioresistant tumour. There are scarce data, but a recent article concluded that particle therapies for skull-based tumours produced minimal symptomatic brain toxicities [28]. We propose to perform a phase I–II trial on carbon ion therapy dose-escalation, with a target dose of 60 Gy (IsoE, the relative biological efficiency

of protons, considered as 1.1), a hypofractionated approach could be considered.

## 3.2. Primitive neuroectodermal tumours (PNET)

### 3.2.1. Medulloblastoma

Medulloblastoma is a primitive neuro-ectodermal tumour (PNET) arising in the cerebellum or the fourth ventricle. It causes the second highest incidence of paediatric tumours (20%) with the mean incidence age of 6 years. The treatment approaches are decided according to age and risk criteria. Risk factors, such as age, quality of resection, metastatic extent, histopathology, cytogenetic and molecular factors, are used for the classification of the tumour [29].

**3.2.1.1. Published studies on the treatment of medulloblastomas.** Craniospinal irradiation is part of the standard treatment for this disease because of the high risk of leptomeningeal spread. Depending on the risk level, either 24 or 36 Gy are delivered to the craniospinal axis, followed by a boost to the primary site and to the metastatic sites, if existing [4,19,30,31] (Table 2). Children under the age of 3 to 5 years are usually treated with surgery followed by intensive chemotherapy to delay radiation therapy. Using such treatment, more than 60% of standard-risk patients (no metastatic disease and no gross residual disease after surgery, favourable histology, and molecular biology) can be cured, but the resulting morbidity can often be high especially regarding cognitive function, altered bone growth, and hormonal deficits.

A dosimetry study published by Saint-Clair et al., in 2004, compared treatments using radiation therapy, intensity-modulated radiation therapy or protontherapy on craniospinal axis irradiation with a posterior fossa boost, in a patient with medulloblastoma [42]. The paper described substantial normal-tissue sparing, mainly cochlea and heart, with intensity-modulated radiation therapy, and even more with protontherapy compared with the conventional radiation therapy. Because of the finite range of proton beams, heart exposure is much lower and cardiac toxicity would be substantially reduced as well as other toxicities to any anterior thoracic structures [4]. Moreover, the higher conformation of the boost delivered, after craniospinal, to the posterior fossa with protons spares the supratentorial brain, particularly the temporal lobes, and the cochlea, this will limit cognitive impairment and hearing loss, as well as avoiding to increase the dose to the pituitary gland, without which is not possible with conformal- or intensity-modulated radiation therapy; this might limit growth hormone disorders and other anterior pituitary deficits.

A recent paper describes the results of protontherapy for medulloblastoma and supratentorial PNET in very young children, which resulted in good disease outcome and low toxicity rates [41]. A point-counterpoint controversy about this approach has been published in a recent issue of the same journal balancing clinical data versus ethical issues for medulloblastoma protontherapy [13]. One side concluded that based on dosimetric studies and emerging clinical evidences, protontherapy is the only ethical approach, whereas the other one questioned the burden of displacement for treatment and emphasized the need for appropriate timing [13,43]. But both sides concluded that all patients should at least be offered a referral for protontherapy in case of medulloblastoma.

There was, up to now, a concern regarding the pattern of failure that may differ because of the steeper dose gradients with protontherapy. A recent paper by the Massachusetts General Hospital on 109 patients gave the pattern of the 16 patients that relapsed and they did not seem to differ from those of patients treated with photon therapy [37].

**Table 2**  
Published studies on the treatment of medulloblastomas in children.

Study	Scheme/Protocol	Treatment			Number of patients	Efficacy	
		Radiotherapy		Chemotherapy		Overall survival	Event-free survival
		Proton	Photon				
<i>Standard risk medulloblastomas</i>							
Taylor et al., 2004 [32]	Chemoradiotherapy Radiotherapy	–	Craniospinal irradiation 35 Gy + posterior fossa 20 Gy, 1.67 Gy/fraction	+	90	3-year: 79.5 %	3-year: 71.6 %
Merchant et al., 2008 [33]		–	Craniospinal irradiation 23.4 Gy + posterior fossa 36 Gy, 1.8 Gy/fraction	–	87	5-year: 70.7 %	5-year: 67.0 %
Packer et al., 2006 [34]	Chemoradiotherapy Chemoradiotherapy	–	Craniospinal irradiation 23.4 Gy + posterior fossa 32.4 Gy, 1.8 Gy/fraction	+	86	NA	5-year: 83.0 %
Oyharcabal-Bourden et al., 2005 [35]		–	Craniospinal irradiation 25 Gy + posterior fossa 55 Gy, 1.8 Gy/fraction	+	379	5-year: 86%	5-year: 81%
Carrie et al., 2009 (MSFOP 98) [3]	Hyperfractionated radiotherapy Standard radiotherapy	–	Craniospinal irradiation: 36 Gy, 1 Gy/fraction, 2 fractions/d + tumour bed (32 Gy)	–	48	3-year: 89%	5-year recurrence-free survival: 64.8 %
Lantering et al., 2012 (PNET4 trial) [36]		–	Craniospinal irradiation: 36 Gy, 1 Gy/fraction twice daily + tumour bed (32 Gy)	+	240	6-year: 78%	6-year: 75%
Sethi et al., 2014 [37]		–	23.4 Gy craniospinal irradiation + boost 30.4 Gy	23.4 Gy craniospinal irradiation + 30.6 Gy boost tumour bed	+	70	5-year: 78%
<i>High-risk medulloblastoma</i>							
Gajjar et al., 2006 [30]	St-Jude medulloblastoma-96	–	Craniospinal irradiation (M0-1, 36 Gy; M2-3.39 Gy) + boost 55.8 Gy local metastasis: 50.4 Gy	+	48	5-year: 70%	11 relapses (median follow-up 38 months)
Taylor et al., 2005 [38]	PNET-3	–	Craniospinal irradiation 35 Gy in 21 fractions + posterior fossa boost 20 Gy in 12 fractions (in 61 patients) Metastatic boost 47.4 Gy in 24 patients	+	68	3-year: 50%	3-year: 40%
Verlooy et al., 2006 [39]	SFOP TC 04/94	–	Posterior fossa 54 Gy, 1.8 Gy/fraction	+	115	5-year: 44%	5-year: 35%
Sethi et al., 2014 [37]		–	36 Gy + boost 18 Gy	+	28	3-year: 68%	3-year: 54%
		–		+		5-year: 60%	5-year: 50%
		–		+			5 relapses (median follow-up 38 months)
<i>Medulloblastomas of young children (&lt; 3 years old)</i>							
Grill et al., 2005 [31]		–	Salvage treatment	Carboplatin, procarbazine, etoposide, cisplatin, vincristine, cyclophosphamide and uromitexan	79	5-year R0M0: 73%	5-year R0M0: 29%
Rutkowski et al., 2005 [40]		–	Salvage treatment	Cyclophosphamide, methotrexate, leucovorin, vincristine, carboplatin, etoposide	43	R1M0: 41%	R1M0: 6%
Jimenez et al., 2013 [41]		–	Craniospinal irradiation 21.6 Gy, boost 54 Gy (relative biological efficiency)	High dose chemotherapy	12	RXM: 13%	RXM: 13%
		–				5-year: 66 ± 7 %	5-year: 58 ± 9%
		–				11 alive at median follow-up of 39 months	1 non-disease related death

**Table 3**  
Published studies on the treatment of supratentorial primitive neuroectodermal tumours in children.

Study	Treatment		Chemotherapy	Number of patients	Efficacy	
	Radiotherapy				Overall survival	Progression-free survival
	Proton	Photon				
Chintagumpala et al., 2009 [47]	–	Craniospinal irradiation 23.4–39 Tumour bed 55.8 Gy	+	16	5-year: 73 %	5-year: 68 %
Pizer et al., 2006 (PNET 3) [48]	–	Craniospinal irradiation 35Gy + boost 20 Gy, 1.67 Gy/fraction	+(51 patients)	68	3-year: 54.4 % 5-year: 48.3 %	3-year: 50.0 % 5-year: 47.0 %
Hong et al., 2004 (CCG 921) [49]	–	Craniospinal irradiation 23.4 Gy-36 Gy + boost 18-21.6 Gy	+	44	NA	3-year: 53 % (M0) 3-year: 14 % (M+)
Timmermann et al., 2006 (HIT-SKK87, HIT-SKK92 trials) [50]	–	Craniospinal irradiation 35.2 Gy in 1.6 Gy/fraction, 5 fractions/week + boost 20 Gy in 2 Gy/fraction, 5 fractions/week (15 patients)	+	29	3-year: 17.2 %	3-year: 14.9 %

3.2.1.2. *Ongoing studies on the treatment of paediatric medulloblastoma.* There is one ongoing study of protons for paediatric medulloblastoma: proton beam radiotherapy for medulloblastoma and pinealoblastoma: an assessment of acute toxicity and long term neurocognitive, neuroendocrine and ototoxicity outcomes NCT01063114 (<http://clinicaltrials.gov/ct2/show/NCT01063114?term=proton+medulloblastoma&rank=1>). This observational monocentric study includes patients between 3 and 25 years of age. The three primary outcome measures are ototoxicity, endocrine dysfunction and neurocognitive effects.

#### Recommendations

As a whole, we would strongly suggest:

- the use of protontherapy for craniospinal irradiation in children;
- for adolescents and young adults, whatever the disease stage, to establish the bone age and then, if growth is complete, to treat only the spinal canal, with safety margins.

#### 3.2.2. Supratentorial PNET

Supratentorial primitive neuroectodermal tumours (SPNET) accounts for 2 to 3% of all paediatric brain tumours. More than 50% occur in the first 5 years of life [44]. PNETs, as medulloblastomas, are classified as embryonal tumours of the central nervous system and histologically correspond to WHO grade IV [45].

The treatment of SPNET is comparable with the one of medulloblastoma, i.e., surgery, chemotherapy, craniospinal irradiation with a localized boost.

Children with SPNET have an even worse prognosis than patients with medulloblastoma because of CSF dissemination and local relapses. Currently, the 5-year survival rate for patients with SPNET is around 31% [46].

The results of several trials are displayed in Table 3. Interestingly, the analysis of the German trials HIT-SKK87 and HIT-SKK92 shows that avoiding radiation therapy in young children decreases dramatically survival [50], and the analysis of prospective German brain-tumour trials, HIT88, 89, and 91 shows statistically significant loss of local control if doses are less than 54 Gy.

In a curative intent in young children having SPNET and undergoing focal or craniospinal irradiation, a high-dose supratentorial boost is indicated. One could expect from a reduced toxicity by

decreasing the dose to normal brain parenchyma thanks to the high dose gradient obtained with proton beams. High precision radiation therapy balance between local control and reduced toxicity suggest the interest, in this rare condition, of a phase II trial.

#### 3.3. Ependymoma

Ependymoma accounts for 8 to 10% of paediatric central nervous system tumours, more than half of the cases occur in children younger than 3 years [51,52], and about 2/3 of these tumours locate in the posterior fossa [53,54].

##### 3.3.1. Treatment of ependymoma

Surgery and radiotherapy are the two main treatments for ependymoma. The resections extent is the most important prognostic factor, but the site of the lesions often located in the pontocerebellar region, can limit surgery due to the intimate involvement of the tumour with the lower cranial nerves and the brainstem. Thus, incomplete resection is frequent. Chemotherapy has little effect on this tumour. It is now recommended to perform a second-look surgery if the first one was incomplete [55]. A post-operative irradiation of 59.4 Gy is recommended for all children older than 3 years [37], and tends now to be extended to children as young as 18 months (Table 4).

The overall survival is around 70% at 5 years in case of complete resection, but it is much lower when there is a residue (R2) [56–58]. New radiation techniques have been introduced into childhood ependymoma treatment. As displayed in Table 4, the Massachusetts General Hospital recently reported the outcome for 70 children with localized ependymoma treated with protons [59,60]. At median follow-up of 46 months, local control and survival were excellent, and the complication rate particularly low. The toxicity of radiation therapy on these young children is a true concern [61,62]. Merchant et al. developed a model that combined dose–volume data with clinical factors to predict intelligence quotient outcomes [63]. Their results contain important information of the radiation effects on normal tissues. The analysis showed that the radiation dose remains the most clinically significant determinant of intelligence quotient outcomes, even low doses, less than 20 Gy, in the supratentorial brain receiving only the diffused dose from the infratentorial radiation therapy, have an impact on final intelligence quotient. Further reduction of the brain volume that receives the highest dose is warranted and protontherapy allows

**Table 4**  
Published studies on the treatment of ependymomas in children.

Author, year	Treatment		Chemotherapy	Number of patients	Efficacy	
	Radiotherapy				Overall survival	Progression-free survival
	Proton	Photon				
Timermann et al., 2000 [56]	–	54 Gy at primary site in 13 patients, 1 Gy/fraction 35.2 Gy craniospinal irradiation (1.5 Gy/fraction) + 20 Gy boost (2.0 Gy/fraction) in 40 patients	+	53	3-year: 75.6% (all)	3-year: 59.7 % (all) 3-year: 83.3 % (complete resection) 3-year: 38.5 % (residual disease)
Massimino et al., 2004 [57]	–	Hyperfractionated radiotherapy 70.4 Gy, 1.1 Gy/fraction twice daily	+ in residual tumour (17 patients)	63	5-year: 75 % (all) 5-year: 82 % (complete response) 5-year: 61 % (residual disease)	5-year: 56 % (all) 5-year: 65 % (complete response) 5-year: 35 % (residual disease)
Merchant et al., 2009 [58]	–	59.4 Gy (131 patients), 1.8 Gy/fraction/d; 54 Gy (22 patients) children < 18 months with complete resection	+ (35 patients)	153	7-year: 81 % 5-year: 93 % (complete resection) 5-year: 52.4 % (R+)	7-year EFS: 69.1 % 7-year local control: 87.3 % 5-year EFS: 81.5 % (complete resection) 5-year EFS: 41 % (R+)
MacDonald et al. [59–61]	55.8 Gy (relative biological efficiency)	–	+ (4 patients)	70	3-year: 95 % 3-year: 97 % (gross total resection) 3-year: 90 % (subtotal resection)	3-year: 76 % 3-year: 88 % (gross total resection) 3-year: 54 % (subtotal resection)

a dramatic reduction of supratentorial brain dose exposure as well as the direct dose to neurosensorial structures.

However, local control remains in the scope of treatment improvements; the possibility to compensate an incomplete surgery by a localized radiation boost with protons is an issue. Actually, in cases of macroscopic postoperative residue, a stereotactic boost of two fractions of 4 Gy has been proposed [64], and will be delivered by photons or protons stereotactic irradiation in the upcoming European prospective trial from SIOP. Whether or not the innovative radiotherapy techniques outperform conformal radiotherapy with better tumour control and neurocognitive outcome will have to be evaluated prospectively with an adequate follow-up. If dose escalation is proposed with protons, the principle of randomization is to be considered.

There is an ongoing protocol in France for re-irradiation of ependymoma local relapses with stereotactic hypofractionated radiotherapy (NCT02013297): <https://clinicaltrials.gov/ct2/show/NCT02013297?term=SBRT&rank=1>. Depending on the future results of this study, in case of residual failure in “high” dose volume, the question of testing carbon ions could be raised.

If protontherapy is indicated for posterior fossa ependymoma as it can spare dose exposure to supratentorial compartments of the brain and auditory structures, supratentorial ependymomas, which are often large, and occur in children over 10 years of age, could represent also a good indication for protons in order to reduce neurocognitive impairments, as illustrated by Fig. 2 [59].

### 3.3.2. Ongoing study on protontherapy for ependymomas

There is only one ongoing prospective study with protons, including ependymoma, it is the one described in the “low grade glioma” section (NCT01288235): <http://clinicaltrials.gov/show/NCT01288235>.

### 3.4. Atypical teratoid rhabdoid tumours

The atypical teratoid rhabdoid tumour of the brain was first identified in 1995. It is a very aggressive and rare tumour, occurring

mainly in very young children. It accounts for 1.5 to 2.1% of paediatric brain tumours [65]. Meningeal metastatic spread is noted in approximately 1/3 of the atypical teratoid rhabdoid tumour cases at the time of diagnosis.

The treatment principles of atypical teratoid rhabdoid tumour consist of surgery resection followed by a variety of chemotherapy regimens with or without radiation therapy. The median survival time ranges from 6 to 11 months. A multi-institutional phase II clinical trial has been conducted to test the efficacy of an aggressive multimodality approach for children with newly diagnosed atypical teratoid rhabdoid tumour, which associate surgery, radiotherapy and chemotherapy. It has resulted in a significant improvement in the time to progression and for the overall survival: the 1-year overall survival and progression-free survival were 75% and 70% respectively [66].

As life expectancy remains unfortunately short in these patients, avoidance of late toxicity is not yet a priority although one group reports offering protontherapy in respect to the very young age of those patients [67].

The current approach for atypical teratoid rhabdoid tumour is combining high-dose chemotherapy and local or craniospinal irradiation with photons.

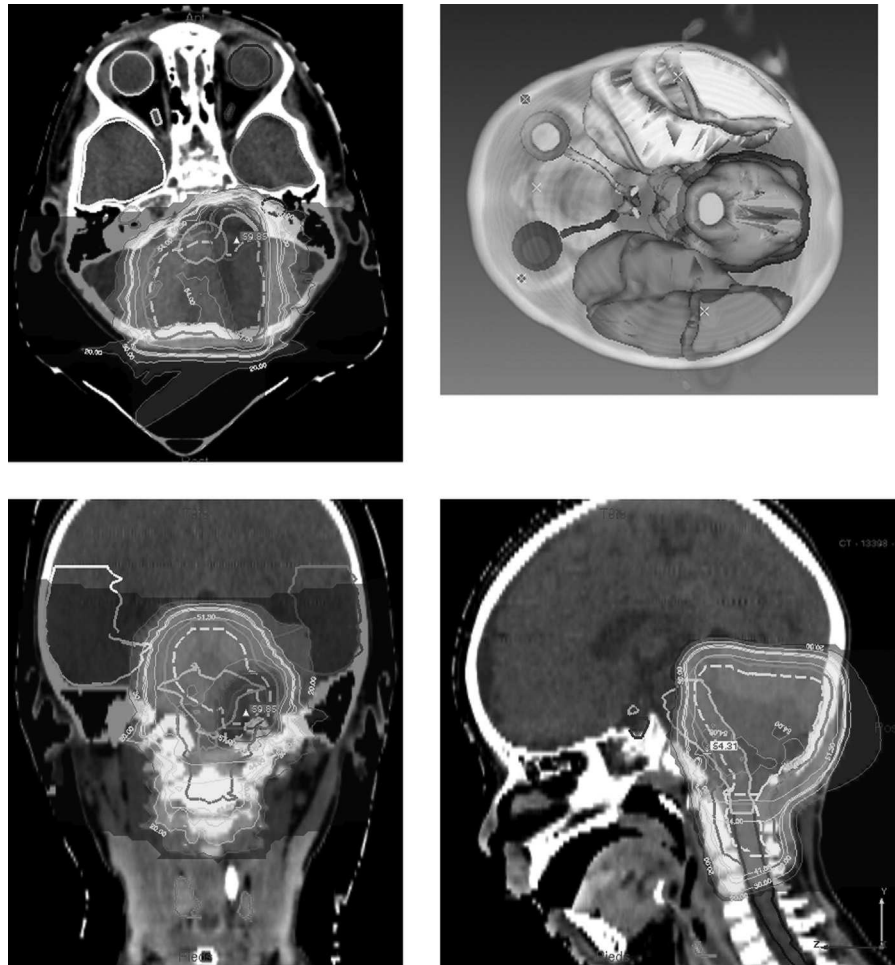
### 3.5. Germ-cell tumours

Germ-cell tumours represent 3 to 5% of childhood brain tumours. They arise mainly in midline suprasellar or pineal structures in adolescents [11]. They are usually localized, but they may disseminate. There are two main subtypes: germinomas and tumours with non-germinomatous components.

#### 3.5.1. Pure non-secreting germinomas

Two-thirds of all central nervous system germ-cell tumours are germinomas [68]. Germinoma is highly sensitive to both radiotherapy and chemotherapy, and has an excellent prognosis with an overall survival of 90% at 10 years [69] (Table 5). Indeed, it has long been a standard to treat using craniospinal irradiation only. In order to reduce radiation related toxicity, recent therapeutic





**Fig. 2.** Radiotherapy of a posterior fossa ependymoma extended to the spine: the dose prescribed was 54 Gy to the tumour bed (lower due to age 2 of the child and tracheotomy) with a boost for a total of 59.4 Gy to the residual tumour and limited dose of 44 Gy to the spine. Note the low dose given to the internal ear (20 Gy) and the absence of dose given to visual structures and the pituitary gland. Courtesy of Dr S. Bolle, centre de protonthérapie d’Orsay.

**Table 5**  
Published studies on the treatment of germ-cell tumours in children.

Study	Treatment		Chemotherapy	Number of patients	Efficacy	
	Radiotherapy				Overall survival	Event-free survival
	Proton	photon				
<i>Non-germinomatous germ-cell tumours treated with radiotherapy</i>						
Kretschmar et al., 2007 [70]	–	Neuroaxis: 50.4 Gy local + 30.6 Gy neuraxis in complete response; 54 Gy local + 36 Gy if less than complete response	+	14	3-year: 79%	5-year PFS: 79%
Calaminus et al., 2013 [71]	–	Focal irradiation 54 Gy	+	96	2-year: 77 %	2-year EFS: 68 %
	–	Craniospinal irradiation 54 Gy	–	26	3-year: 68 %	3-year EFS: 72 %
<i>Germinomas treated with radiotherapy</i>						
Kretschmar et al., 2007 [70]	–	30.6–54 Gy	+	12	3-year: 100 %	5-year PFS: 92 %
Calaminus et al., 2013 [71]	–	Option A	+	113	NA	3-year EFS: 93 %
	–	Option B	+	57		2-year EFS: 90 %
Bamberg et al., 1999 [69]	–	Focal irradiation: 40 Gy Craniospinal irradiation 36 Gy + boost 14 Gy, or craniospinal irradiation 30 Gy + boost 15 Gy	+	60	5-year: 93.7 %	5-year EFS: 87.6 %
Bouffet et al., 1999 [72]	–	40 Gy, craniospinal irradiation, 25–30 Gy in case of disseminated germinoma	+	57	3-year: 98%	3-year EFS: 96.4%

PFS: progression-free survival; EFS: event-free survival.

practice of localized germinomas has used a combined approach with chemotherapy followed by radiation therapy limited to the tumour bed, which has led to good survival [71]. However, a specific pattern of relapse has been observed within ventricles, with no or a very low rate of craniospinal relapse [70,72,73]. Thus, an approach with whole ventricular radiation therapy, plus a localized boost, has been suggested and could yield an equivalent survival with an expected reduced long-term toxicity [74].

Actually, although general cognitive abilities appeared stable and intact after treatment for most children with central nervous system germ-cell tumours, a significant decline over time in working memory, processing speed, and visual memory was observed in a study of longitudinal evaluation of neurocognitive function after treatment for 35 germ-cell tumours [75]. After examination of the impact of radiation field, Mabbott et al. found that patients treated with craniospinal irradiation performed poorly, relative to those treated with ventricular volumes, on measures of intellectual function, reading, and receptive vocabulary. However, the location of the tumour was also predictive of the extent of detriment. These results suggest that attempts at reducing radiation volumes in patients with central nervous system germ-cell tumours and in particular patients with germinoma are supported by long-term differences cognitive outcomes [75].

However, the coverage of such a complex shape, as the whole ventricles, means that a significant volume of the brain receives a significant dose of radiation therapy [76]. A recent retrospective study from Massachusetts General Hospital described the outcome for 22 children with protontherapy where 100% local control was achieved. Substantial normal-tissue sparing was seen when intensity-modulated radiation therapy was compared to the different proton treatments: i.e. conformal protontherapy (passive scattering or scanning), or intensity modulated protontherapy. This latter technique allowed additional sparing [77,78].

#### Recommendations

Given the excellent survival rates in both localized and metastatic conditions with, respectively, localized and craniospinal irradiation, we would recommend that all patients should benefit from proton therapy, or at least the younger ones, i.e. less than 12 years of age.

In SIOP studies, germinoma with a teratoma component receive whole ventricular irradiation followed by a higher 54 Gy total dose to the primary if incomplete surgery.

#### 3.5.2. Non-germinomatous germ-cell tumours

Non-germinomatous germ-cell tumours occur in younger patients around 10 years of age, it is an heterogeneous entity with frequently several components combining choriocarcinoma, yolk-sac tumour, embryonic carcinoma with survival rates at 5 years around 60% [14,68,73,79]. Postoperative residue together with elevated AFP markers is of prognosis value.

#### 3.5.3. Ongoing studies on the treatment of germ-cell tumours

A European prospective non randomized trial for the diagnosis and treatment of children, adolescents and adults with intracranial germ-cell tumours, is opening in most French centres: SIOP CNS GCT II, <http://clinicaltrials.gov/ct2/show/NCT01424839?term=germ+cell+tumours&recr=Open&intr=radiotherapy&rank=1>. For localised germinoma, patients receive primary chemotherapy followed by radiation treatment to whole ventricular system up to 24 Gy. Only in cases with non-complete response to chemotherapy after centralized review, an additional boost of 16 Gy bringing total dose to 40 Gy is delivered to the primary site. For metastatic

germinoma, a craniospinal irradiation at 24 Gy followed by a boost of 16 Gy (total dose 40 Gy) is delivered. For non-germinomatous malignant germ-cell tumours: if localized, 54 Gy are delivered to the primary site, if metastatic, a craniospinal irradiation of 30 Gy plus a boost of 24 Gy (total dose 54 Gy) to primary site and intracranial metastases is delivered, and a boost of 20 Gy for spinal metastases.

A specific protontherapy study is ongoing at the Massachusetts General Hospital: phase II study of proton radiation therapy for central nervous system germ cell tumours: evaluation of acute and late side effects (NCT01049230), delivering local, ventricular or craniospinal protontherapy.

#### 3.6. Craniopharyngioma

Craniopharyngioma is the third most common intracranial tumour in children, with the majority of cases occurring between 5 and 14 years of age. This histologically benign tumour of epithelial origin is located, in 70% of cases, in the retrochiasmatic region, often extending into the third ventricle, along the hypothalamus, close to cerebral arteries, optic tracks, the pituitary gland, the hippocampal formation, and cranial nerves. Therefore, its insidious growth can cause severe damages and can even be, at last, life threatening. In addition, its localization is very challenging for safe radiotherapy delivery. Obesity, one of the most deleterious side-effects of therapy is purely attributable to surgery.

##### 3.6.1. Published studies on the treatment of craniopharyngiomas

According to the presentation, two treatment options are proposed: either primary total resection or, particularly in case of hypothalamic involvement, conservative limited surgery followed by external-beam irradiation.

The relapse rate for surgery alone is approximately 20 to 70%, depending on the extent of the resection. Radiation therapy, after subtotal resection, improves the local control rate at 10 years to approximately 80 to 85% [80,81]. Habrand et al. reported, in 1999, very encouraging results from 25 years of experience in children treated with radiation therapy by using conformal radiation therapy combined or not with surgical resection at a single institution. The 5-year overall survival rate was 90% using doses between 45 and 56 Gy [81].

As craniopharyngioma is a benign tumour, a stereotactic radiation therapy approach is warranted when it is small in volume. However, as it is often located close to the optic pathways, a fractionated treatment maybe more adequate than radiosurgery [82,83]. Indeed, in a study of 21 patients (11 children and 10 adults) treated by radiosurgeries, Ulfarsson et al. described 38% visual complications and 63% of relapses [84]. Merchant et al. published, in 2006, the results of a phase II trial with conformal radiation therapy using photons, which had excellent local control, and concluded that the security margins could be safely reduced from 20 mm to 10 mm (nowadays, standard margins vary from 3 to 5 mm), while significantly decreasing radiation doses to the brain and, therefore, improving probability of intelligence quotient preservation [85]. The percentage of total brain, supratentorial brain, or left temporal lobe volumes receiving a dose in excess of 45 Gy had a significant impact on longitudinal intelligence quotient. More recently, a series, with doses ranging from 50 to 55 Gy of protons, gave local control for 14 out of 15 patients with no later adverse visual effects [86]. Another series of preliminary results of 15 patients (5 children and 10 adults, median age of 36 years) from Massachusetts General Hospital, with mixed photon and proton beams, and a median dose of 56 Gy (IsoE), described a 93% 5-year local-control rate [87]. A recent work from the MD Anderson Cancer Center compared tumour coverage and doses to organs at risk in 10 paediatric patients with

**Table 6**  
Published studies on the treatment of craniopharyngiomas in children.

Study	Treatment		Number of patients	Efficacy	
	Proton	Photon		Overall survival	Progression-free survival
Merchant et al., 2006 [85]	–	Conformal radiotherapy: 54–55.8 Gy, 1.8 Gy/fraction	28	NA	3-year: 90.3%
Amendola et al., 2003 [89]	–	Gamma knife radiosurgery Mean dose <sub>min</sub> 14 Gy (11–20 Gy) Mean dose <sub>max</sub> 29 Gy (24–40 Gy)	14	100% (mean follow-up 39 months)	Local control: 12/14 (mean follow-up 39 months)
Minniti et al., 2007 [82]	–	Stereotactic conformal radiotherapy: 50–55 Gy, 30–33 fractions in 6–6.5 weeks	39	3-year: 100 % 5-year: 100 %	3-year: 97 % 5-year: 92 %
Luu et al., 2006 [86]	Protonbeam radiotherapy: 50.4–59.4 CGE, 1.8 CGE/fraction, 5 fractions/week	–	16	12/15 (mean follow-up 60.2 months)	Local control: 14/15 (mean follow-up 60.2 months)

CGE: cobalt gray equivalent.

craniopharyngioma treated with intensity-modulated radiation therapy, 3D-protontherapy, or intensity-modulated protontherapy [88]. A significant reduction in dose to the hippocampal (–51.3%) and vascular structures was obtained with protontherapy (Table 6).

### 3.6.2. Ongoing studies on the treatment of craniopharyngioma

A phase II trial of limited surgery and proton therapy for craniopharyngioma and observation for craniopharyngioma after radical resection is driven at the Curie Paris Orsay institute: <http://clinicaltrials.gov/ct2/show/NCT01419067?term=craniopharyngioma+proton&rank=1>.

The goal of this study is to determine the feasibility and safety of a limited surgery and a 5-mm clinical target volume margin in combination with protontherapy when surgery is incomplete (R2). The primary outcome measures are progression-free survival and overall survival.

An ongoing French phase II study driven at Curie Paris Orsay institute evaluates the feasibility of increasing the dose up to 59.5 Gy with respect of dose constraint to the optic pathway, with protontherapy after incomplete conservative surgery.

### Recommendations

Radiation therapy has been described as providing long-term disease control for most patients. However, there has been much concern about the potential impact of radiation therapy for craniopharyngioma on growth, development, performance, and quality of life. The risk of losing vision or stroke is an additional concern [90,91]. Moreover, the potential risk of radiation-induced second cancer has argued against its use, although there are no data reporting an increased rate of secondary cancer after radiation therapy for craniopharyngioma. Muller et al. reported that quality of life for craniopharyngioma was negatively only related to hypothalamic involvement, tumour size, and the number of neurosurgical interventions. There was no impact of conventional radiotherapy on hypothalamic function [92]. As endocrine deficiencies are frequently due to tumour growth or surgery that precedes radiation therapy, radiation should not be avoided in an effort to prevent an endocrine deficit [85]. As volumes could be large and organ at risk limiting, the accurate ballistic of protontherapy should improve the outcome of craniopharyngioma when irradiation is needed.

### 3.7. Toxicity studies

Below is a synthesis of the main benefits expected on the following organs at risk.

#### 3.7.1. Brain

Cognitive impairments due to radiotherapy may be lowered by the significant decrease of dose around the target volume [86].

#### 3.7.2. Pituitary gland

Hormonal deficiency is very common after brain tumour irradiation as growth hormone deficiency occurs very frequently above a dose of 18 Gy and thyroid stimulating hormone and adrenocorticotrophic hormone deregulations above 40 Gy. Protontherapy reduces significantly the dose to the pituitary gland, avoiding unnecessary irradiation [59].

#### 3.7.3. Auditory structures

Auditory structures are very sensitive as a median dose of 35 Gy represents a high risk for auditory deficit. Irradiation of the posterior fossa, the most frequent site of paediatric brain tumours, at doses of 50 to 60 Gy, elicits high doses to these structures, even with intensity-modulated radiation therapy; protontherapy allows a much better protection [63].

#### 3.7.4. Visual structures

As an example, the use of protons allows to deliver 59 Gy in residual craniopharyngiomas while preserving chiasm, as evaluated in the current French prospective protocol described above [86].

#### 3.7.5. Brainstem

A comparative study in infratentorial ependymoma showed a significant decrease of dose on brainstem [59]. This may be very beneficial for these tumours often situated in the pontocerebellar angle; as a reduction in dose due to brainstem constraints would not be necessary anymore with protons.

#### 3.7.6. Late effects of protontherapy

Better information about late effects has to be obtained through prospective studies especially carried out for such assessment. Through open paediatric protocols for patients treated with protontherapy, the investigators of the following clinical studies aim

to define and report the acute and late effects associated with treatment:

- outcomes study of late effects after proton radiotherapy for paediatric tumours of the brain, head, and neck (CN01, Florida, NCT01067196);
- neurobehavioral functioning in paediatric brain tumour patients after proton beam radiation treatment (Massachusetts General Hospital, NCT01180881);
- proton radiotherapy for paediatric brain tumours requiring partial brain irradiation (Massachusetts General Hospital, NCT01288235);
- prospective assessment of quality of life in paediatric patients treated with radiation therapy for brain tumours and non-central nervous system malignancies.

### 3.8. Second cancers

Another side effect that should be reduced with protontherapy is second cancers, the potential influence of improved dose-distribution with protontherapy was evaluated on a dosimetric study of paediatric medulloblastoma: the incidence of second cancers was expected to be reduced by a factor 5 to 8 [93]. A review by Hall underlined that “*The benefit of protons could be achieved if a scanning beam was used in which the doses are 10 times lower than with intensity-modulated radiation therapy*” [94]. A more recent retrospective study on 558 patients, among whom 44 paediatric cases, reports a second cancer rate of 5.2% for adult proton patients versus 7.5% for adult photon patients and none in paediatric patients but the follow-up of the whole cohort was short (6.7 years), and patients had been mainly treated with passive scattering method [95]. Further specific paediatric studies are needed with a more detailed analysis of the site of second cancers compared to the first cancer treatment site, when using scanning proton beam.

### 3.9. Cost-effectiveness of protontherapy in a paediatric setting

The base-case study using a Markov cohort-simulation model by Lundkvist et al. showed that protontherapy applied in medulloblastoma was associated with € 23,600 in cost savings and 0.68 additional quality-adjusted life-years per patient [96]. Interestingly, the analyses showed that this achievement was mainly obtained through the reduction of late toxicity. Actually, reductions in intelligence quotient loss and growth hormone deficiency contributed to the greatest part of the cost savings and were the most important parameters for cost-effectiveness.

This type of study shows which improvement could be expected from a larger use of protontherapy when toxicity issues are the main concern.

### 3.10. Results of the indications recommended by the group of paediatric radiation oncology

The literature analysis is in favour of the use of proton therapy for paediatric brain tumour in a curative intent, either for focal irradiation (localized ependymoma; germ-cell tumours; craniopharyngioma; low-grade glioma), whole-ventricular irradiation (germinoma), or craniospinal irradiation (medulloblastoma, disseminated germ-cell tumours). Therefore, the eligible population in France would represent approximately 300 children and 100 adolescents and young adults each year.

## 4. Discussion

Paediatric radiotherapy is often considered as a two-edged weapon. On one edge, a necessary and efficient treatment for

children’s solid tumour, particularly brain tumours, on the other edge, a source of mild to severe late effects: cognitive, endocrinal, auditory and visual. In the everyday practice of paediatric radiation oncology, the question of referral to a protontherapy centre is frequent but resources are scarce and no national guidelines exist for paediatric brain tumour. This prompted us to analyse literature for hadrontherapy indications in children in order to make recommendations and evaluate the number of children that would benefit from a protontherapy treatment in France. We have detailed above for each tumour type the benefit expected from protontherapy as well as discussed cost-effectiveness.

Carbon ions therapy is just emerging in adults and has not been yet applied to very young patients. However, benefit for high-grade glioma or diffuse intrinsic pontine glioma might be questioned as primary care or treatment at relapse.

Concerning protontherapy, literature data is in favour of neurocognitive, sensorial and endocrine benefits with protons compared to photons for all paediatric patients treated for brain tumours in a curative intent. Actually, the physics of protontherapy allow outstanding ballistics to target the tumour area, while substantially decreasing radiation dose to the surrounding normal tissues. Results from this literature analysis are in favour of decreased late effects without drawback on survival. The literature analysis is in favour of the use of proton therapy for paediatric brain tumour in a curative intent, either for focal irradiation, whole-ventricular irradiation, or craniospinal irradiation. We analysed carefully the incidence of all brain tumours within the children and adolescents and young adults population in France published by Sommelet et al., Lacour et al. and Désandes et al. [97–99]. The eligible population in France, following our recommendations, for conventional dose protontherapy in a curative setting represents 315 children and 95 adolescents and young adults per year, reaching 410 patients per year.

Many ongoing prospective clinical trials will allow evaluating the efficacy and toxicity of protontherapy. With increasing medical imaging tumour evaluation, one can also suggest that protontherapy could be also used for dose-escalation on resistant tumours, without increased healthy tissue irradiation. An elegant approach could be dose-painting, i.e. increasing dose to radioresistant clusters identified by molecular imaging [100,101]. The paediatric ependymoma photons protons and imaging (PEPPI) study is currently driven by the Périclès team in collaboration with France Hadron and the radiotherapy committee of the French society of paediatric oncology. This retrospective study analyses all anatomic and metabolic imaging, as well as treatment plans of 227 paediatric patients with a newly diagnosed ependymoma treated in the French paediatric radiotherapy reference centres [102]. The aim of this study is to define new biological target volumes [103] and perform multicentric in silico dose painting dosimetric studies comparing photons and protons with the ambition of a future dose-painting proton prospective trial.

## 5. Conclusion

In France, 600 children every year receive a radiotherapy and brain tumours radiation therapy is the most frequent indication. To this, we can add the adolescents and young adults population. The number of indications for protons in a curative setting in paediatric and adolescents and young adults with brain tumours is 410 per year. Therefore, the need for protontherapy for such internationally acknowledged development, added to the other recognized and reimbursed indications (other paediatric and young adults cancers, ocular melanomas, base of skull, spinal and paraspinal tumours, low grade sarcomas, selected head and neck carcinomas) is not covered by the single existing protontherapy facility in France at

Orsay and will not be covered by the additional upcoming facility, in Nice. Additional protontherapy centres with children-dedicated equipment are needed to offer equal access to this therapy. These centres should include general anaesthesia capacity, trained team and could be cost-efficient.

## Disclosure of interest

The authors declare that they have no competing interest.

## References

- [1] Jones B, Wilson P, Nagano A, Fenwick J, McKenna G. Dilemmas concerning dose distribution and the influence of relative biological effect in proton beam therapy of medulloblastoma. *Br J Radiol* 2012;85:e912–8.
- [2] Habrand JL, Datchary J, Alapetite C, Bolle S, Calugaru V, Feuvret L, et al. Update of clinical programs using hadrontherapy 2008–2012. *Cancer Radiother* 2013;17:400–6.
- [3] Carrie C, Grill J, Figarella-Branger D, Bernier V, Padovani L, Habrand JL, et al. Online quality control, hyperfractionated radiotherapy alone and reduced boost volume for standard risk medulloblastoma: long-term results of MSFOP 98. *J Clin Oncol* 2009;27:1879–83.
- [4] Fossati P, Ricardi U, Orecchia R. Paediatric medulloblastoma: toxicity of current treatment and potential role of protontherapy. *Cancer Treat Rev* 2009;35:79–96.
- [5] Peñagaricano J, Moros E, Corry P, Saylor R, Ratanatharathorn V. Paediatric craniospinal axis irradiation with helical tomotherapy: patient outcome and lack of acute pulmonary toxicity. *Int J Radiat Oncol Biol Phys* 2009;75:1155–61.
- [6] Fuss M, Hug EB, Schaefer RA, Nevinny-Stickel M, Miller DW, Slater JM, et al. Proton radiation therapy (PRT) for paediatric optic pathway gliomas: comparison with 3D planned conventional photons and a standard photon technique. *Int J Radiat Oncol Biol Phys* 1999;45:1117–26.
- [7] Combs SE, Schulz-Ertner D, Moschos D, Thilmann C, Huber J, Debus J. Fractionated stereotactic radiotherapy of optic pathway gliomas: tolerance and long-term outcome. *Int J Radiat Oncol Biol Phys* 2005;62:814–9.
- [8] Merchant TE, Kun LE, Wu S, Xiong X, Sanford RA, Boop FA. Phase II trial of conformal radiation therapy for paediatric low-grade glioma. *J Clin Oncol* 2009;27:3598–604.
- [9] Hug EB, Menter MW, Archambeau JO, DeVries A, Liwnicz B, Loredano LN, et al. Conformal proton radiation therapy for paediatric low-grade astrocytomas. *Strahlenther Onkol* 2002;178:10–7.
- [10] MacDonald TJ, Arenson EB, Ater J, Sposito R, Bevan HE, Deutsch M, et al. Phase II study of high-dose chemotherapy before radiation in children with newly diagnosed high-grade astrocytoma: final analysis of Children's Cancer Group Study 9933. *Cancer* 2005;104:2862–71.
- [11] Finlay JL, Boyett JM, Yates AJ, Wisoff JH, Milstein JM, Geter JR, et al. Randomized phase III trial in childhood high-grade astrocytoma comparing vincristine, lomustine, and prednisone with the eight-drugs-in-1-day regimen. *J Clin Oncol* 1995;13:112–23.
- [12] Awdeh RM, Kiehna EN, Drewry RD, Kerr NC, Haik BG, Wu S, et al. Visual outcomes in paediatric optic pathway glioma after conformal radiation therapy. *Int J Radiat Oncol Biol Phys* 2012;84:46–51.
- [13] Johnstone PA, McMullen KP, Buchsbaum JC, Douglas JG, Helft P. Paediatric CSI: are protons the only ethical approach? *Int J Radiat Oncol Biol Phys* 2013;87:228–30.
- [14] Dearnaley DP, A'Hern RP, Whittaker S, Bloom HJ. Pineal and CNS germ cell tumours: Royal Marsden Hospital experience 1962–1987. *Int J Radiat Oncol Biol Phys* 1990;18:773–81.
- [15] Merchant TE, Conklin HM, Wu S, Lustig RH, Xiong X. Late effects of conformal radiation therapy for paediatric patients with low-grade glioma: prospective evaluation of cognitive, endocrine, and hearing deficits. *J Clin Oncol* 2009;27:3691–7.
- [16] Broniscer A, Gajjar A. Supratentorial high-grade astrocytoma and diffuse brainstem glioma: two challenges for the paediatric oncologist. *Oncologist* 2004;9:197–206.
- [17] Rieken S, Habermehl D, Wuertl L, Brons S, Mohr A, Lindel K, et al. Carbon ion irradiation inhibits glioma cell migration through downregulation of integrin expression. *Int J Radiat Oncol Biol Phys* 2012;83:394–9.
- [18] Chan AA, Lau A, Pirzkall A, Chang SM, Verhey LJ, Larson D, et al. Proton magnetic resonance spectroscopy imaging in the evaluation of patients undergoing gamma knife surgery for grade IV glioma. *J Neurosurg* 2004;101:467–75.
- [19] Combs SE, Burkholder I, Edler L, Rieken S, Habermehl D, Jäkel O, et al. Randomised phase I/II study to evaluate carbon ion radiotherapy versus fractionated stereotactic radiotherapy in patients with recurrent or progressive gliomas: the Cinderella trial. *BMC Cancer* 2010;10:533.
- [20] Packer RJ, Allen JC, Goldwein JL, Newall J, Zimmerman RA, Priest J, et al. Hyperfractionated radiotherapy for children with brainstem gliomas: a pilot study using 7200 cGy. *Ann Neurol* 1990;27:167–73.
- [21] Prados MD, Wara WM, Edwards MS, Larson DA, Lamborn K, Levin VA. The treatment of brain stem and thalamic gliomas with 78 Gy of hyperfractionated radiation therapy. *Int J Radiat Oncol Biol Phys* 1995;32:85–91.
- [22] Lewis J, Lucraft H, Gholkar A, United Kingdom Childhood Cancer Study Group. UKCCSG study of accelerated radiotherapy for paediatric brain stem gliomas. *Int J Radiat Oncol Biol Phys* 1997;38:925–9.
- [23] Kalifa C, Valteau D, Pizer B, Vassal G, Grill J, Hartmann O. High-dose chemotherapy in childhood brain tumours. *Childs Nerv Syst* 1999;15:498–505.
- [24] Bouffet E, Raquin M, Doz F, Gentet JC, Rodary C, Demeocq F, et al. Radiotherapy followed by high dose busulfan and thiotepa: a prospective assessment of high dose chemotherapy in children with diffuse pontine gliomas. *Cancer* 2000;88:685–92.
- [25] Haas-Kogan DA, Banerjee A, Kocak M, Prados MD, Geyer JR, Fouladi M, et al. Phase I trial of tipifarnib in children with newly diagnosed intrinsic diffuse brainstem glioma. *Neuro Oncol* 2008;10:341–7.
- [26] Combs SE, Steck I, Schulz-Ertner D, Welze LT, Kulozik AE, Behnisch W, et al. Long-term outcome of high-precision radiotherapy in patients with brain stem gliomas: results from a difficult-to-treat patient population using fractionated stereotactic radiotherapy. *Radiother Oncol* 2009;91:60–6.
- [27] Laprie A, Pirzkall A, Haas-Kogan DA, Cha S, Banerjee A, Le TP, et al. Longitudinal multivoxel MR spectroscopy study of paediatric diffuse brainstem gliomas treated with radiotherapy. *Int J Radiat Oncol Biol Phys* 2005;62:20–31.
- [28] Miyawaki D, Murakami M, Demizu Y, Sasaki R, Niwa Y, Terashima K, et al. Brain injury after proton therapy or carbon ion therapy for head-and-neck cancer and skull base tumours. *Int J Radiat Oncol Biol Phys* 2009;75:378–84.
- [29] Monje M, Beachy PA, Fisher PG. Hedgehogs, flies, wnts and MYCs: the time has come for many things in medulloblastoma. *J Clin Oncol* 2011;29:1395–8.
- [30] Gajjar A, Chaintagumpala M, Ashley D, Kellie S, Kun LE, Merchant TE, et al. Risk-adapted craniospinal radiotherapy followed by high-dose chemotherapy and stem-cell rescue in children with newly diagnosed medulloblastoma (St-Jude Medulloblastoma-96): long-term results from a prospective, multicentre trial. *Lancet Oncol* 2006;7:813–20.
- [31] Grill J, Sainte-Rose C, Jouvett A, Gentet JC, Lejars O, Frappaz D, et al. Treatment of medulloblastoma with postoperative chemotherapy alone: an SFOP prospective trial in young children. *Lancet Oncol* 2005;6:573–80.
- [32] Taylor RE, Bailey CC, Robinson KJ, Weston CL, Ellison D, Ironside J, et al. Impact of radiotherapy parameters on outcome in the International Society of Paediatric Oncology/United Kingdom Children's Cancer Study Group PNET-3 study of preradiotherapy chemotherapy for M0-M1 medulloblastoma. *Int J Radiat Oncol Biol Phys* 2004;58:1184–93.
- [33] Merchant TE, Kun LE, Krasin MJ, Wallace D, Chintagumpala MM, Woo SY, et al. Multi-institution prospective trial of reduced-dose craniospinal irradiation (23.4 Gy) followed by conformal posterior fossa (36 Gy) and primary site irradiation (55.8 Gy) and dose-intensive chemotherapy for average-risk medulloblastoma. *Int J Radiat Oncol Biol Phys* 2008;70:782–7.
- [34] Packer RJ, Gajjar A, Vezina G, Rorke-Adams, Burger PC, Robertson L, et al. Phase III study of craniospinal radiation therapy followed by adjuvant chemotherapy for newly diagnosed average-risk medulloblastoma. *J Clin Oncol* 2006;24:4202–8.
- [35] Oyharcabal-Bourden V, Kalifa C, Gentet JC, Frappaz D, Edan C, Chastagner P, et al. Standard-risk medulloblastoma treated by adjuvant chemotherapy followed by reduced-dose craniospinal radiation therapy: a French Society of Paediatric Oncology Study. *J Clin Oncol* 2005;23:4726–34.
- [36] Lannering B, Rutkowski S, Doz F, Pizer B, Gustafsson G, Navajas A, et al. Hyperfractionated versus conventional radiotherapy followed by chemotherapy in standard-risk medulloblastoma: results from the randomized multicenter HIT-SIOP PNET 4 trial. *J Clin Oncol* 2012;30:3187–93.
- [37] Sethi RV, Giansoudi D, Raiford M, Malhi I, Niemierko A, Rapalino O, et al. Patterns of failure after proton therapy in medulloblastoma; linear energy transfer distributions and relative biological effectiveness associations for relapses. *Int J Radiat Oncol Biol Phys* 2014;88:655–63.
- [38] Taylor RE, Bailey CC, Robinson KJ, Weston CL, Walker DA, Ellison D, et al. Outcome for patients with metastatic (M2-3) medulloblastoma treated with SIOP/UKCCSG PNET-3 chemotherapy. *Eur J Cancer* 2005;41:727–34.
- [39] Verlooy J, Mosseri V, Bracard S, Tubiana AL, Kalifa C, Pichon F, et al. Treatment of high risk medulloblastomas in children above the age of 3 years: a SFOP study. *Eur J Cancer* 2006;42:3004–14.
- [40] Rutkowski S, Bode U, Deinlein F, Ottensmeier H, Warmuth-Metz M, Soerensen N, et al. Treatment of early childhood medulloblastoma by postoperative chemotherapy alone. *N Engl J Med* 2005;352:978–86.
- [41] Jimenez RB, Sethi R, Depauw N, Pulsifer MB, Adams J, McBride SM, et al. Proton radiation therapy for paediatric medulloblastoma and supratentorial primitive neuroectodermal tumours: outcomes for very young children treated with upfront chemotherapy. *Int J Radiat Oncol Biol Phys* 2013;87:120–6.
- [42] Saint-Clair WH, Adams JA, Bues M, Fullerton BC, La Shell S, Kooy HM, et al. Advantage of protons compared to conventional X-ray or IMRT in the treatment of a paediatric patient with medulloblastoma. *Int J Radiat Oncol Biol Phys* 2004;58:727–34.
- [43] Wolden SL. Protons for craniospinal radiation: are clinical data important? *Int J Radiat Oncol Biol Phys* 2013;87:231–2.
- [44] Klisch J, Husstedt H, Hennings S, Velthoven V, Pagenstecher A, Schumacher M. Supratentorial primitive neuroectodermal tumours: diffusion-weighted MRI. *Neuroradiology* 2000;42:393–8.
- [45] Louis DN, Ohgaki H, Wiestler OD, Cavenee WK. WHO classification of tumours of the central nervous system. Lyon: IARC; 2007. p. 132–46.

- [46] Geyer JR, Sposto R, Jennings M, Boyett JM, Axtell RA, Breiger D, et al. Multiagent chemotherapy and deferred radiotherapy in infants with malignant brain tumors: a report from the Children's Cancer Group. *J Clin Oncol* 2005;23:7621–31.
- [47] Chintagumpala M, Hassall T, Palmer S, Ashley D, Wallace D, Kasow K, et al. A pilot study of risk-adapted radiotherapy and chemotherapy in patients with supratentorial PNET. *Neuro Oncol* 2009;11:33–40.
- [48] Pizer BL, Weston CL, Robinson KJ, Ellison DW, Ironside J, Saran F, et al. Analysis of patients with supratentorial primitive neuro-ectodermal tumours entered into the SIOP/UKCCSG PNET 3 study. *Eur J Cancer* 2006;42:1120–8.
- [49] Hong TS, Mehta MP, Boyett JM, Donahue B, Rorke LB, Yao MS, et al. Patterns of failure in supratentorial primitive neuroectodermal tumors treated in Children's Cancer Group Study 921, a phase III combined modality study. *Int J Radiat Oncol Biol Phys* 2004;60:204–13.
- [50] Timmermann B, Kortmann RD, Kuhl J, Rutkowski S, Meisner C, Pietsch T, et al. Role of radiotherapy in supratentorial primitive neuroectodermal tumour in young children: results of the German HIT-SKK87 and HIT-SKK92 trials. *J Clin Oncol* 2006;24:1554–60.
- [51] Merchant TE. Current management of childhood ependymoma. *Oncology (Williston Park)* 2002;16:629–42 [644; discussion 64–6, 648].
- [52] Koshy M, Rich S, Merchant TE, Mahmood U, Regine WF, Kwok Y. Postoperative radiation improves survival in children younger than 3 years with intracranial ependymoma. *J Neurooncol* 2011;105:583–90.
- [53] Grill J, Le Deley MC, Gambarelli D, Raquin MA, Couanet D, Pierre-Kahn A, et al. Postoperative chemotherapy without irradiation for ependymoma in children under 5 years of age: a multicenter trial of the French Society of Paediatric Oncology. *J Clin Oncol* 2001;19:1288–96.
- [54] McGuire CS, Sainani KL, Fisher PG. Both location and age predict survival in ependymoma: a SEER study. *Pediatr Blood Cancer* 2009;52:65–9.
- [55] Massimino M, Solero CL, Garrè ML, Biassoni V, Cama A, Genitori L, et al. Second-look surgery for ependymoma: the Italian experience. *J Neurosurg* 2011;8:246–50.
- [56] Timmermann B, Kortmann RD, Kuhl J, Meisner C, Slavc L, Pietsch T, et al. Combined postoperative irradiation and chemotherapy for anaplastic ependymomas in childhood: results of the German prospective trials HIT 88/89 and HIT 91. *Int J Radiat Oncol Biol Phys* 2000;46:287–95.
- [57] Massimino M, Gandola L, Giangaspero F, Sandri A, Valagussa P, Perilongo G, et al. Hyperfractionated radiotherapy and chemotherapy for childhood ependymoma: final results of the first prospective AIEOP (Associazione Italiana di Ematologia-Oncologia Paediatrica) study. *Int J Radiat Oncol Biol Phys* 2004;58:1336–45.
- [58] Merchant TE, Li C, Xiong X, Kun LE, Boop FA, Sanford RA. Conformal radiotherapy after surgery for paediatric ependymoma: a prospective study. *Lancet Oncol* 2009;10:258–66.
- [59] Macdonald SM, Sethi R, Lavally B, Yeap BY, Marcus KJ, Caruso P, et al. Proton radiotherapy for paediatric central nervous system ependymoma: clinical outcomes for 70 patients. *Neuro Oncol* 2013;15:1552–9.
- [60] MacDonald SM, Yock TI. Proton beam therapy following resection for childhood ependymoma. *Childs Nerv Syst* 2010;26:285–91.
- [61] MacDonald SM, Safai S, Trofimov A, Wolfgang J, Fullerton B, Yeap BY, et al. Proton radiotherapy for childhood ependymoma: initial clinical outcomes and dose comparisons. *Int J Radiat Oncol Biol Phys* 2008;71:979–86.
- [62] Beltran C, Naik M, Merchant TE. Dosimetric effect of setup motion and target volume margin reduction in paediatric ependymoma. *Radiation Oncol* 2010;96:216–22.
- [63] Merchant TE, Kiehna EN, Li C, Xiong X, Mulhern RK. Radiation dosimetry predicts IQ after conformal radiation therapy in paediatric patients with localized ependymoma. *Int J Radiat Oncol Biol Phys* 2005;63:1546–54.
- [64] Timmermann B, Kortmann RD, Kuhl J, Meisner C, Dieckmann K, Pietsch T, et al. Role of radiotherapy in the treatment of supratentorial primitive neuroectodermal tumours in childhood: results of the prospective German brain tumour trials HIT 88/89 and 91. *J Clin Oncol* 2002;20:842–9.
- [65] Heck JE, Lombardi CA, Cockburn M, Meyers TJ, Wilhelm M, Ritz B. Epidemiology of rhabdoid tumours of early childhood. *Pediatr Blood Cancer* 2013;60:77–81.
- [66] Chi SN, Zimmerman MA, Yao X, Cohen KJ, Burger P, Biegel JA, et al. Intensive multimodality treatment for children with newly diagnosed CNS atypical teratoid rhabdoid tumour. *J Clin Oncol* 2009;27:385–9.
- [67] De Amorim Bernstein K, Sethi R, Trofimov A, Zeng C, Fullerton B, Yeap BY, et al. Early clinical outcomes using proton radiation for children with central nervous system atypical teratoid rhabdoid tumours. *Int J Radiat Oncol Biol Phys* 2013;86:114–20.
- [68] Jennings MT, Gelman R, Hochberg F. Intracranial germ-cell tumours: natural history and pathogenesis. *J Neurosurg* 1985;63:155–67.
- [69] Bamberg M, Kortmann RD, Calaminus G, Becker G, Meisner C, Harms D, et al. Radiation therapy for intracranial germinoma: results of the German cooperative prospective trials MAKEI 83/86/89. *J Clin Oncol* 1999;17:2585–92.
- [70] Kretschmar C, Kleinberg L, Greenberg M, Burger P, Holmes E, Wharam M. Pre-radiation chemotherapy with response-based radiation therapy in children with central nervous system germ cell tumours: a report from the Children's Oncology Group. *Pediatr Blood Cancer* 2007;48:285–91.
- [71] Calaminus G, Kortmann R, Worch J, Nicholson JC, Alapetite C, Garrè ML, et al. SIOP CNS GCT 96: final report of outcome of a prospective, multinational nonrandomized trial for children and adults with intracranial germinoma, comparing craniospinal irradiation alone with chemotherapy followed by focal primary site irradiation for patients with localized disease. *Neuro Oncol* 2013;15:788–96.
- [72] Bouffet E, Baranzelli MC, Patte C, Portas M, Edan C, Chastagner P, et al. Combined treatment modality for intracranial germinomas: results of a multicentre SFOP experience. *Br J Cancer* 1999;79:1199–204.
- [73] Alapetite C, Puget S, Bolle S, Datchary J, Noël G, Nauraye C, et al. Protontherapy for craniopharyngioma in children: the Orsay proton center experience. [Proceedings of the 2010 SIOP meeting; abstract]. Boston: SIOP; 2010.
- [74] Finlay J, da Silva NS, Lavey R, Bouffet E, Kellie SJ, Shaw E, et al. The management of patients with primary central nervous system (CNS) germinoma: current controversies requiring resolution. *Pediatr Blood Cancer* 2008;51:313–6.
- [75] Mabbott DJ, Monsalves E, Spiegler BJ, Bartels U, Janzen L, Guger S, et al. Longitudinal evaluation of neurocognitive function after treatment for central nervous system. *Cancer* 2011;117:5402–11.
- [76] Raggi E, Mosleh-Shirazi MA, Saran FH. An evaluation of conformal and intensity-modulated radiotherapy in whole ventricular radiotherapy for localised primary intracranial germinomas. *Clin Oncol (R Coll Radiol)* 2008;20:253–60.
- [77] MacDonald SM, Trofimov A, Safai S, Adams J, Fullerton B, Ebb D, et al. Proton radiotherapy for paediatric central nervous system germ cell tumours: early clinical outcomes. *Int J Radiat Oncol Biol Phys* 2011;79:121–9.
- [78] Alapetite C, De Marzi L, Zefkili S, Dauphinot C, Amessis M, Brisse H, et al. Whole ventricular irradiation for children with localised intracranial germinoma: arguments for proton therapy in comparison to IMRT and tomotherapy. *Neuro Oncol* 2010;12:ii40 [abstract].
- [79] Hoffman HJ, Otsubo H, Hendrick EB, Humphreys RP, Drake JM, Becker LE, et al. Intracranial germ-cell tumours in children. *J Neurosurg* 1991;74:545–51.
- [80] Habrand JL, Saran F, Alapetite C, Noel G, El Boustany R, Grill J. Radiation therapy in the management of craniopharyngioma: current concepts and future developments. *J Pediatr Endocrinol Metab* 2006;19:389–94.
- [81] Habrand JL, Ganry O, Couanet D, Rouxel V, Lévy-Piedbois C, Pierre-Kahn A, et al. The role of radiation therapy in the management of craniopharyngioma: a 25-year experience and review of the literature. *Int J Radiat Oncol Biol Phys* 1999;44:255–63.
- [82] Minniti G, Saran F, Traish D, Sooma IR, Sardell S, Gonsalvez A, et al. Fractionated stereotactic conformal radiotherapy following conservative surgery in the control of craniopharyngiomas. *Radiation Oncol* 2007;82:90–5.
- [83] Schulz-Ertner D, Frank C, Herfarth KK, Rhein B, Wannenmacher M, Debus J. Fractionated stereotactic radiotherapy for craniopharyngiomas. *Int J Radiat Oncol Biol Phys* 2002;54:1114–20.
- [84] Ulfarsson E, Lindquist C, Roberts M, Rahn T, Lindquist M, Thorén M, et al. Gamma knife radiosurgery for craniopharyngiomas: long-term results in the first Swedish patients. *J Neurosurg* 2002;97:613–22.
- [85] Merchant TE, Kiehna EN, Kun LE, Mulhern RK, Li C, Xiong X, et al. Phase II trial of conformal radiation therapy for paediatric patients with craniopharyngioma and correlation of surgical factors and radiation dosimetry with change in cognitive function. *J Neurosurg* 2006;104:94–102.
- [86] Luu QT, Loredò LN, Archambeau JO, Yonemoto LT, Slater JM, Slater JD. Fractionated proton radiation treatment for paediatric craniopharyngioma: preliminary report. *Cancer J* 2006;12:155–9.
- [87] Fitzek MM, Linquod RM, Adams J, Munzenrider JE. Combined proton and photon irradiation for craniopharyngioma: long-term results of the early cohort of patients treated at Harvard Cyclotron Laboratory and Massachusetts General Hospital. *Int J Radiat Oncol Biol Phys* 2006;64:1348–54.
- [88] Boehling NS, Grosshans DR, Bluett JB, Palmer MT, Song X, Amos RA, et al. Dosimetric comparison of three-dimensional conformal proton radiotherapy, intensity-modulated proton therapy, and intensity-modulated radiotherapy for treatment of paediatric craniopharyngiomas. *Int J Radiat Oncol Biol Phys* 2012;82:643–52.
- [89] Amendola BE, Wolf A, Coy SR, Amendola MA. Role of radiosurgery in craniopharyngiomas: a preliminary report. *Med Pediatr Oncol* 2003;41:123–7.
- [90] Müller HL, Gebhardt U, Etavard-Gorris N, Korenke E, Warmuth-Metz M, Kolb R, et al. Prognosis and sequela in patients with childhood craniopharyngioma – results of HIT-ENDO and update on Kraniopharyngioma 2000. *Klin Padiatr* 2004;216:343–8.
- [91] Müller HL, Gebhardt U, Pohl F, Flentje M, Emser A, Warmuth-Metz M, et al. Relapse pattern after complete resection and early progression after incomplete resection of childhood craniopharyngioma. *Klin Padiatr* 2006;218:315–20.
- [92] Müller HL, Bruhnken G, Emser A, Faldum A, Etavard-Gorris N, Gebhardt U, et al. Longitudinal study on quality of life in 102 survivors of childhood craniopharyngioma. *Childs Nerv Syst* 2005;21:975–80.
- [93] Miralbell R, Lomax A, Cella L, Schneider U. Potential reduction of the incidence of radiation-induced second cancers by using proton beams in the treatment of paediatric tumours. *Int J Radiat Oncol Biol Phys* 2002;54:824–9.
- [94] Hall EJ. Intensity-modulated radiation therapy, protons, and the risk of second cancers. *Int J Radiat Oncol Biol Phys* 2006;65:1–7.
- [95] Chung CS, Yock TI, Nelson K, Xu Y, Keating NL, Tarbell NJ. Incidence of second malignancies among patients treated with proton versus photon radiation. *Int J Radiat Oncol Biol Phys* 2013;87:46–52.
- [96] Lundkvist J, Ekman M, Ericsson SR, Jönsson B, Glimelius B. Cost-effectiveness of proton radiation in the treatment of childhood medulloblastoma. *Cancer* 2005;103:793–801.
- [97] Sommelet D, Clavel J, Lacour B. *Épidémiologie des cancers de l'enfant*. Paris: Springer Verlag France; 2009.

- [98] Lacour B, Goujon S, Guissou S, Guyot-Goubin A, Desmée S, Désandes E, et al. Childhood cancer survival in France, 2000–2008. *Eur J Cancer Prev* 2014;23:449–57.
- [99] Désandes E, Lacour B, Belot A, Molinie F, Delafosse P, Tretarre B, et al. Cancer incidence and survival in adolescents and young adults in France. *Pediatr Hematol Oncol* 2013;30:291–306.
- [100] Ken S, Vieillevigne L, Franceries X, Simon L, Supper C, Lotterie JA, et al. Integration method of 3D MR spectroscopy into treatment planning system for glioblastoma IMRT dose painting with integrated simultaneous boost. *Radiat Oncol* 2013;8:1.
- [101] Supiot S, Lisbona A, Paris F, Azria D, Fenoglietto P. “Dose-painting”: myth or reality? *Cancer Radiother* 2010;14:554–62.
- [102] Ducassou A, Murraciale X, Chaltiel L, Bolle S, Claude L, Bernier V, et al. Role of age, grade and RT dose on outcome of 177 ependymoma – 13 years experience of Child’s Cancer French Society. *Radiother Oncol* 2015;115:S155 [3rd ESTRO Forum, abstract OC-0309].
- [103] Tensaouti F, Ducassou A, Liceaga S, Lotterie JA, Sevely A, Peran P, et al. Identification of significant biological subvolume from MRI in paediatric ependymoma related to treatment outcome. *Radiother Oncol* 2015; 115:S154–5 [3rd ESTRO Forum, abstract OC-0308].